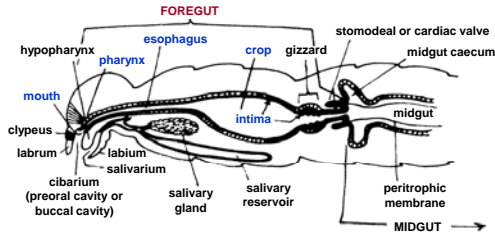
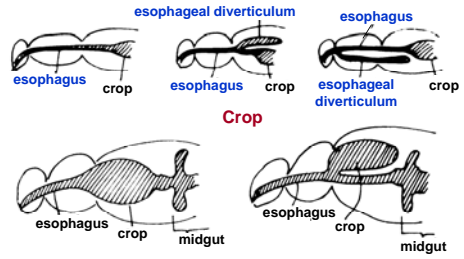


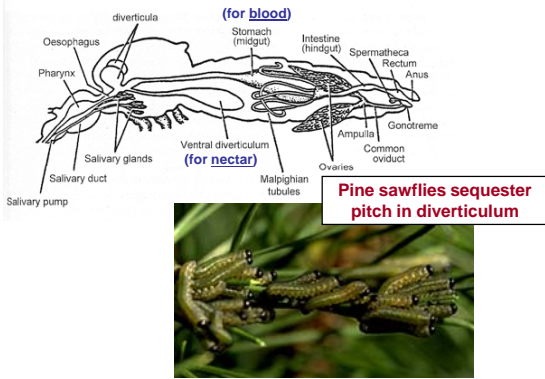
Alimentary tract: esophagus and crop



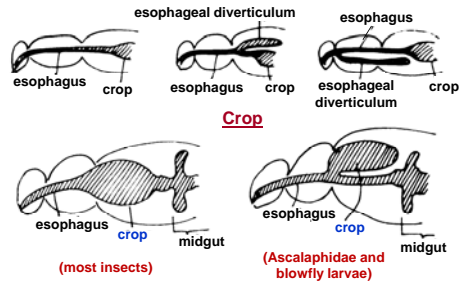
Esophagus



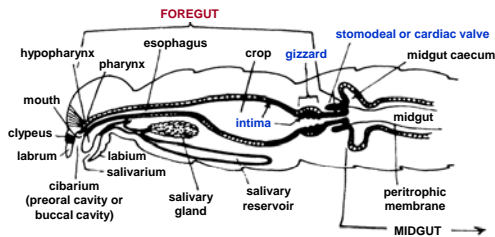
Example: esophageal diverticulum in *Anopheles*



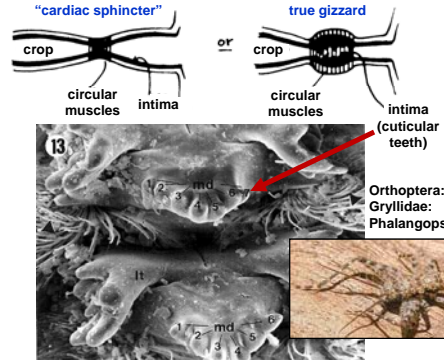
Esophagus



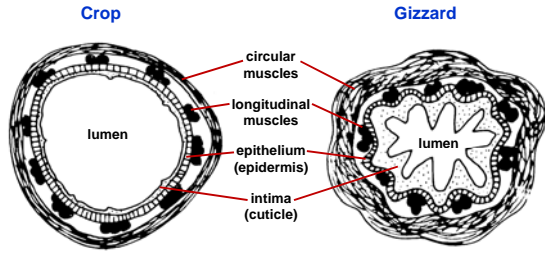
Alimentary tract: the gizzard



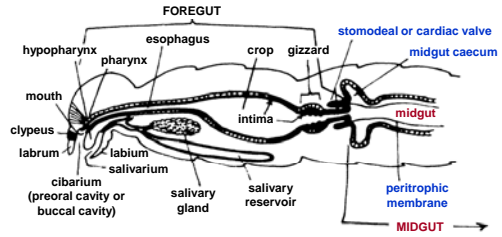
Gizzard (proventriculus)



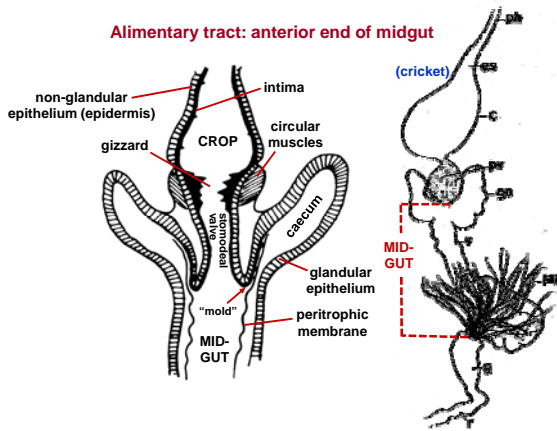
Histology of the foregut



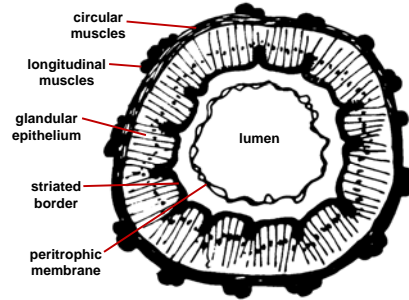
Alimentary tract: foregut/midgut transition



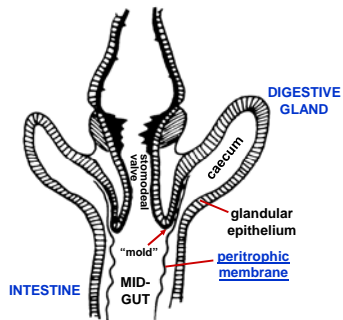
Alimentary tract: anterior end of midgut



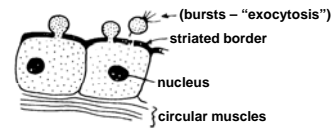
Histology of the midgut



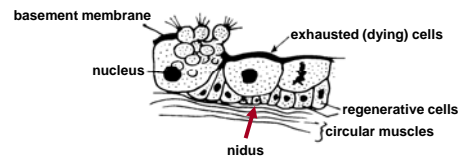
Digestion and the peritrophic membrane

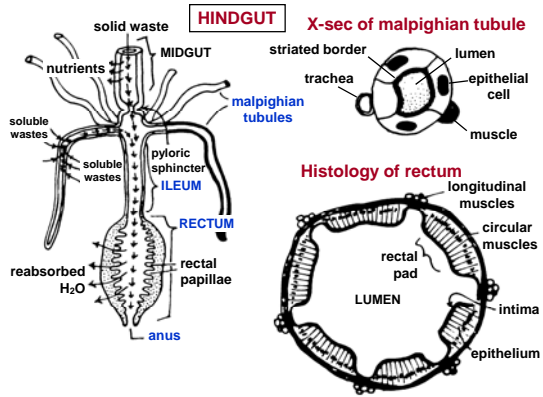


Merocrine (eccrine) secretion

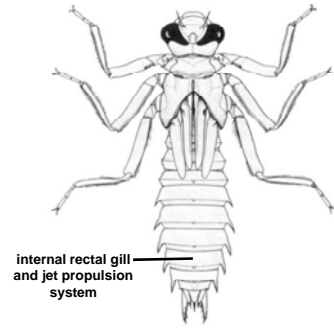


Holocrine secretion





Rectal jets & gills in Odonata: dragonfly naiad



Rectal silk & anal spinnerets: Neuroptera (Chrysopidae)



Rectal chemical explosions

